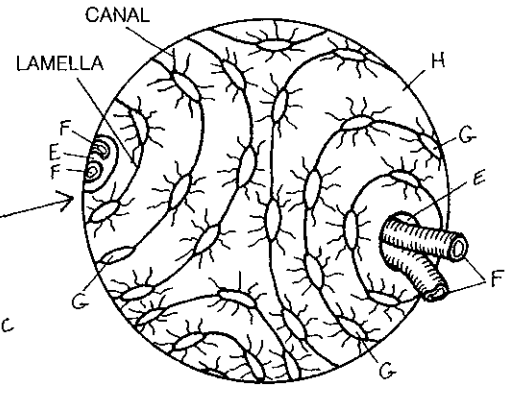
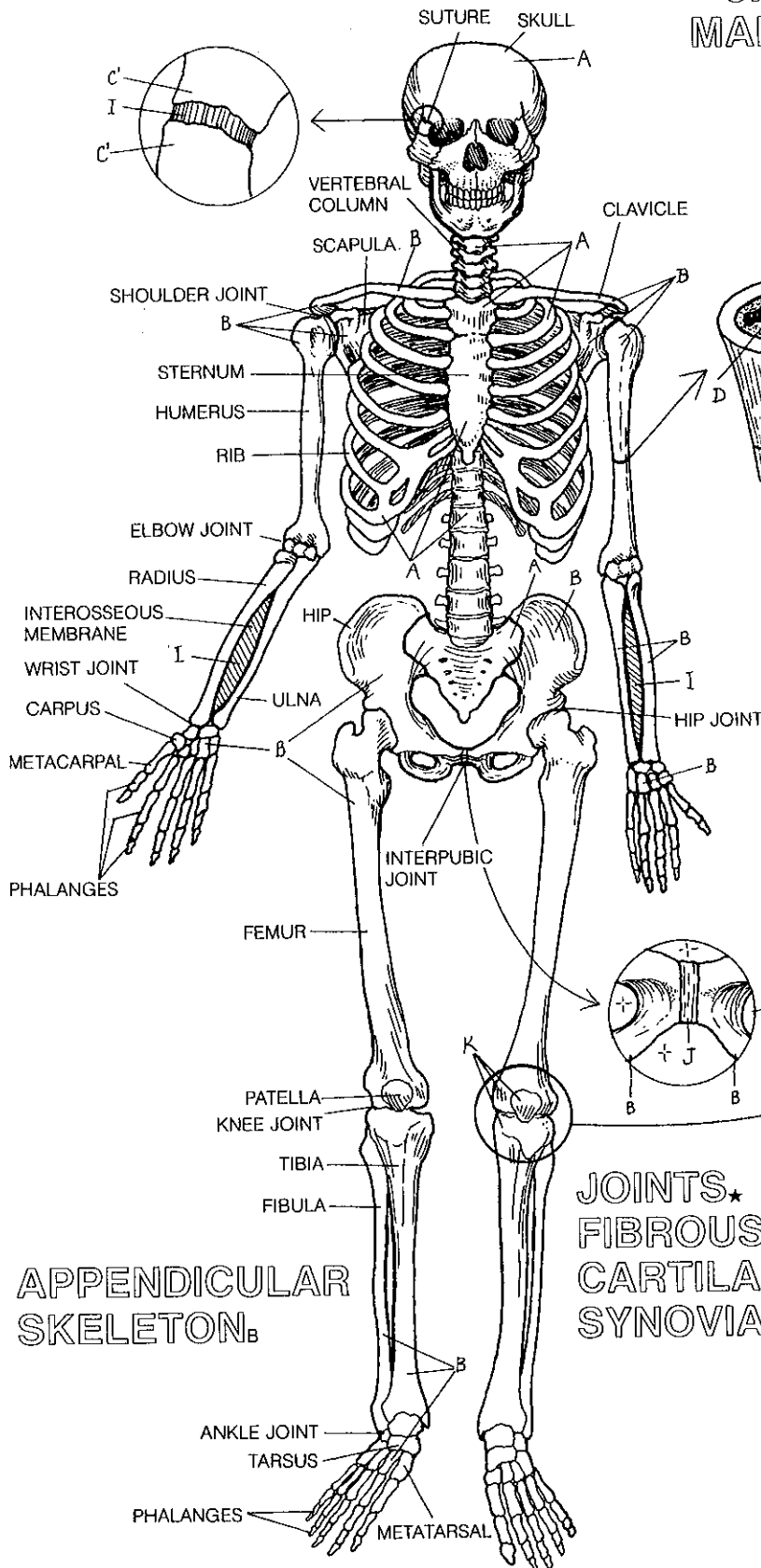


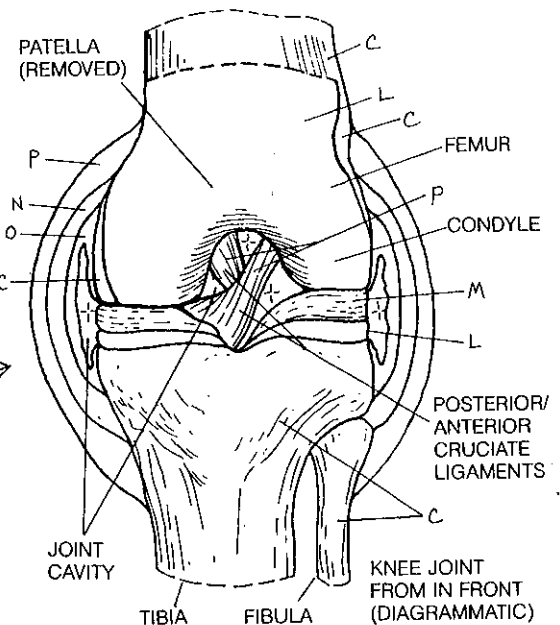
# SKELETAL SYSTEM.

## AXIAL SKELETON<sub>A</sub>

BONE★  
COMPACT.  
CANCELLOUS.  
MARROW CAVITY.



HAVERSIAN SYSTEM★  
HAVERSIAN CANAL<sub>E</sub>  
VESSEL<sub>F</sub>  
OSTEOCYTE<sub>G</sub>  
MINERALIZED MATRIX<sub>H</sub>



JOINTS★  
FIBROUS.  
CARTILAGE.  
SYNOVIAL<sub>K</sub>

ARTICULAR CARTILAGE.  
MENISCUS<sub>M</sub>  
JOINT CAPSULE<sub>N</sub>  
SYNOVIAL MEMBRANE.  
LIGAMENT<sub>P</sub>